

# TMJ

## A Holistic View of Temporomandibular Joint Syndrome

John E. Upledger, D.O., O.M.M.

### INTRODUCTION

**D**uring the 1980s, temporomandibular joint syndrome (TMJ) really came into its own. Today, it is still a very popular diagnosis. Myriad mechanical devices have been designed and placed in people's mouths to alleviate the symptoms related to TMJ. Most of these devices were designed to correct temporomandibular joint dysfunction through bite/occlusion modification and/or the reduction of joint compression. The success rate of the singular use of such devices leaves something to be desired. All too often symptomatic relief is only partially achieved and is dependent upon the ongoing use of these well-intended, intra-oral appliances. That is, when the "splint" comes out the symptoms often return to their original intensity.

My experience strongly suggests that TMJ pain is quite often the "tip of the iceberg." Dysfunction of the temporomandibular joint is frequently a secondary or tertiary manifestation of another problem or problems within the whole person.

Underlying problems that contribute to temporomandibular joint dysfunction and secondary symptoms are often found in the craniosacral, nervous, musculoskeletal, myofascial and masticatory systems. Temporomandibular joint syndrome may also be secondary to, or be receiving significant contributions from, previous or current physical traumatic injuries anywhere in the body and from stress, be it physical, physiological, psychoemotional and/or environmental. In addition, there may also be systemic disease processes in the background, as well as allergic and/or nutritional factors that can and often do significantly contribute to the presenting temporomandibular joint syndrome.

Before we go into the myriad potential causes and contributing factors, let's take a brief look at the symptoms that may present secondary to a temporomandibular joint dysfunction. Usually several but seldom all of these symptoms present in a single patient.

There may be pain directly within the temporomandibular joint, and it may be in one or both sides. This pain may be constant, or only occur when the temporomandibular joints are put in motion as the patient chews, bites or simply moves the jaw a bit. The temporomandibular joints may click, snap or produce crepitation when moved. When the mouth opens and closes, its path of movement may be a "zigzag" rather than straight up and down. There may be only one "zig" in the path or there may be a whole zigzag, depending on the patient's situation. In severe cases, the range of motion of the lower jaw may be reduced or the mouth may be "stuck" open or closed.

There is often moderate to severe pain that may be constant or episodic in the head (headache — sometimes originally thought of as migraine), neck (more often in the upper cervical region), upper thoracic spine and scapula regions. There are often painful triggers that signal their presence when touched/palpated in the cervical and upper thoracic regions.

The patient may also have tinnitus (a ringing in the ears), which may be either episodic or constant. Visual acuity may be reduced. Ability to concentrate and focus attention is frequently impaired. It is not uncommon for the TMJ syndrome to include significant personality changes. These patients will often show increased irritability, depression, self-pity, self-focus and hypochondriasis.

*"Underlying problems that contribute to temporomandibular joint dysfunction and secondary symptoms are often found in the craniosacral, nervous, musculoskeletal, myofascial and masticatory systems."*



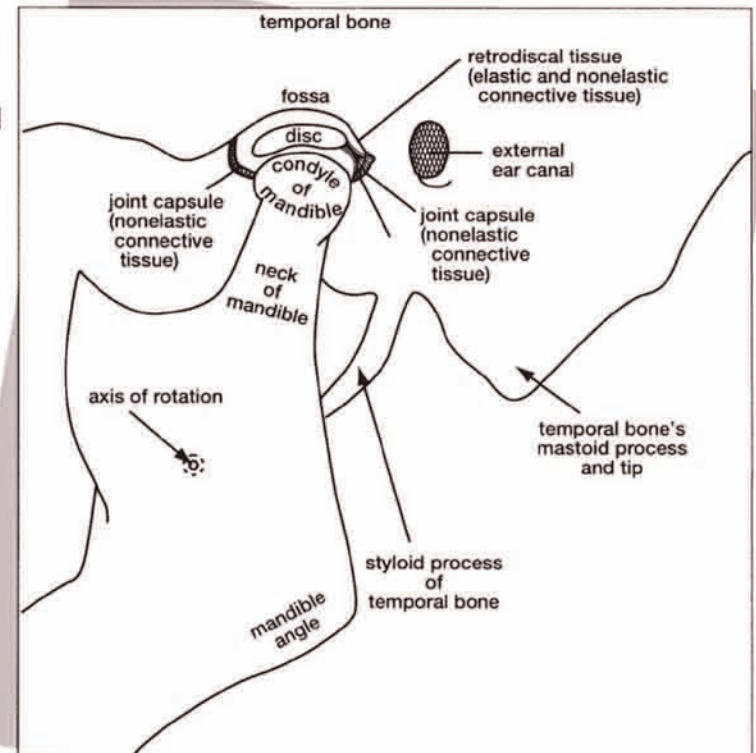
## The Joints

**Figure 1: The  
Temporomandibular  
Joint**

**T**he temporomandibular joints are located just a couple of centimeters forward from the ear canal on both sides of the head. Each temporomandibular joint is actually made up of two joints, one on top of the other. The lower of the two joints is between the condyles of the mandible on both sides of the head and the discs that are interposed between these condyles and the temporal bones. The upper joints are located between the interposed discs and the surfaces of the fossae and eminences of the temporal bones on each side of the head.

A connective tissue capsule surrounds the "double" joint, and connective tissue completely seals off the upper joint from the lower one. All joint surfaces have cells that secrete synovial fluid into the joints. This lubricating fluid is therefore contained in two separate and independent compartments on each side of the head.

The special design of each of the temporomandibular joints allows for the axis of rotation of the mandible to be located two or three centimeters below the joint on the mandibular ramus on each side. This situation causes the mandibular condyles to move forward when the mouth is open. While in the open-mouth position, the anterior part of the mandible is in a lowered position in relationship to the upper jaw. It is theorized that the purpose (and it seems to me that nature does everything for a purpose) for the forward motion of the mandibular condyles when



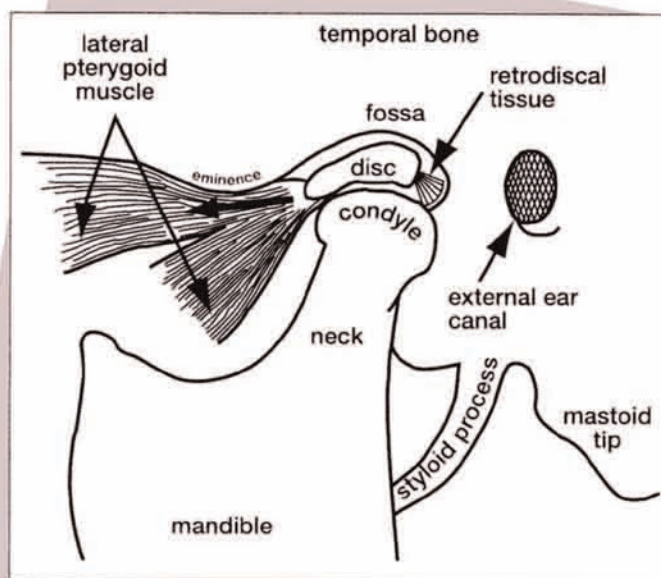
**Figure 1**

the mouth is opened is to protect the delicate temporal bones and other structures located between the temporal fossa joint surfaces and the ear canals.

In order for the discs to remain interposed between the joint surfaces of the temporal bones and the mandibular condyles during opening and closing movements of the mouth, it is mandatory that the discs be able to move forward and backward over the condylar surfaces of the mandible. This movement of the discs over the condyles is accomplished by the design of the attachments of the discs to the condyles and the interplay of forces controlling disc positions within the temporomandibular joints. First, the movement of the discs is allowed because each disc is attached to each condyle only by collateral ligaments on the medial and lateral aspects of the condyle. This allows for a forward and backward gliding of the

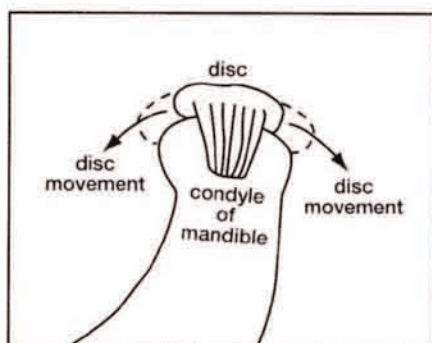
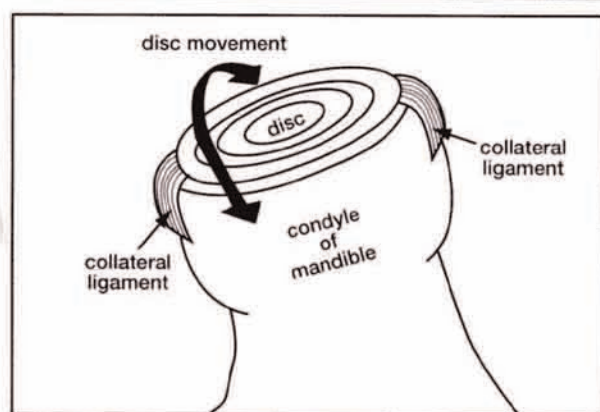
discover the condylar surface as the disc is called upon to remain interposed between the mandibular condyle and the temporal joint surfaces.

The disc's position within the temporomandibular joint is controlled by reciprocal activity between the lateral pterygoid muscle (which, when contracted, moves the disc forward) and elastic tissue connecting the posterior aspect of the disc to the posterior aspect of the joint capsule. The retrodiscal elastic tissue causes the return of the disc to a posterior position when the lateral pterygoid muscle relaxes. So you can see that the lateral pterygoid muscle contracts against the resistance of the retrodiscal elastic tissue.



**Figure 2**

**Figure 2: The Forces Upon the Disc**



It is also of interest that the bony components of the temporomandibular joints are constructed so that they are able to reconstruct and repair damage better than almost any other joint in the body. Therefore, if excessive pressure, wear and tear are reduced significantly, the joint will rejuvenate.

To assist this rejuvenation process, good nutrition and improvement of the physiological environment are of utmost importance.

**Figure 3**

**Figure 3: Disc Mobility on the Condyle**

The collateral ligaments are so designed to allow the disc to move over the surface of the mandibular condyle so that it can remain interposed between the condyle and the temporal fossa during joint motion.



## The Muscles

**T**he muscles of mastication, when considered in detail, are a small book in and of themselves. We shall therefore give a brief overview of the major muscles here.

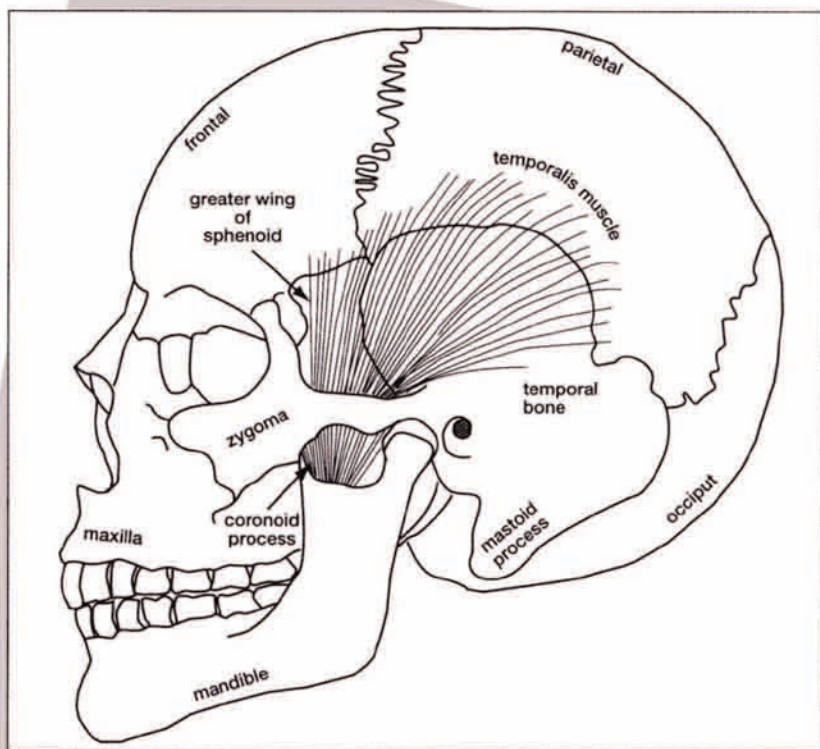
These muscles are the temporalis, masseter, medial pterygoid, lateral pterygoid, buccinator and the floor of the mouth, which is composed of the mylohyoideus, geniohyoideus and anterior belly of the digastricus muscle. They are all paired muscles.

**The Temporalis Muscle** - The temporalis muscle arises from the floor of the temporal fossa. It attaches to parts of the external skull surfaces of the parietal bones, the squama of temporal bones, the frontal bone and the great wings of the sphenoid bone. The insertions of the temporalis muscles are into the coronoid processes and the rami of the mandible on both sides.

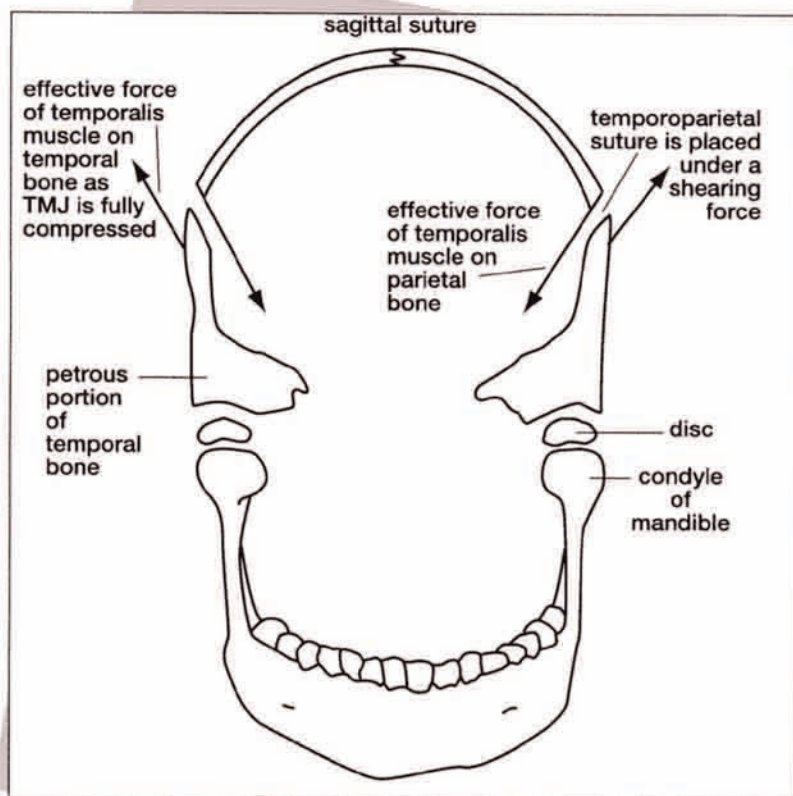
The temporalis muscle actually divides into three regions, which seem to have the ability to act independently. They are the anterior, middle and posterior regions. The anterior region protrudes the mandible forward when it contracts. The middle region pulls the mandible upward to forcibly close the mouth, and the posterior region more forcibly closes the mouth by pulling the coronoid process of the mandible diagonally into retraction and upward closure (Figures 4 below and 5 at right).

Another very interesting aspect of temporalis muscle contraction is that it has the ability to pull the parietal bone contributions to the temporoparietal suture down into the V-shaped receiving area formed by the upper borders of the two temporal bone squama. This downward pull results when the mandible is prevented from moving down by the insertions of the temporalis muscles, and the temporomandibular

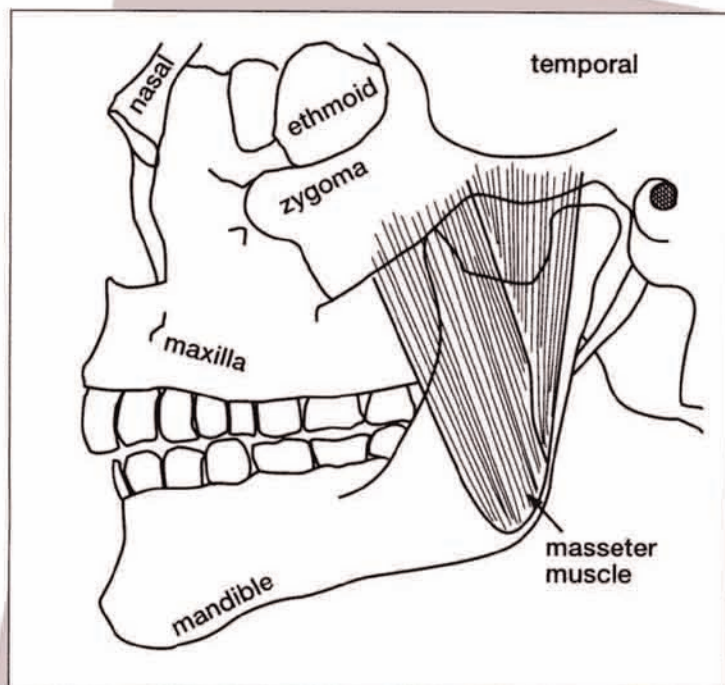
**Figure 4: The Temporalis Muscle**



**Figure 4**



**Figure 5**



**Figure 6**

joints are fully compressed so that the temporal bones can not move down any further. The last movable connections of the temporalis muscles are the lateral aspects of the parietal bones. This continued downward force by the temporalis muscles causes a shearing distortion and stress within the temporoparietal sutures, as well as an eventually destructive compression upon the discs and bony surfaces of the temporomandibular joints. Excessive and habitual temporalis muscle contraction is often emotionally induced.

**The Mandibular Sling** - The masseter and medial pterygoid muscles form what has become known as the "mandibular sling." They suspend the angle of the mandible in a sling of muscle and fascia. The masseter muscle forms the external component of the sling. The medial pterygoid muscle forms the internal component. The masseter's origin is the zygomatic arch, and its insertion is the lateral aspect of the mandibular ramus.

**Figure 5: Effect of Extreme Temporalis Hypertonus or Contraction**

**Figure 6: The Masseter Muscle Component of the Mandibular Sling**



## Figure 7: The Pterygoid Muscles

The medial pterygoid muscles attach on the inside of the rami opposite the masseter attachments on both sides of the mandible. The upper attachments, or origins, of the medial pterygoid muscles are from the lateral pterygoid plates of the sphenoid, from the smaller pyramidal process of the palatine bone, and from the tuberosity of the maxilla. The medial pterygoid muscles are in two parts on each side of the head at their upper origins. They blend into one part down lower near their attachments at the rami.

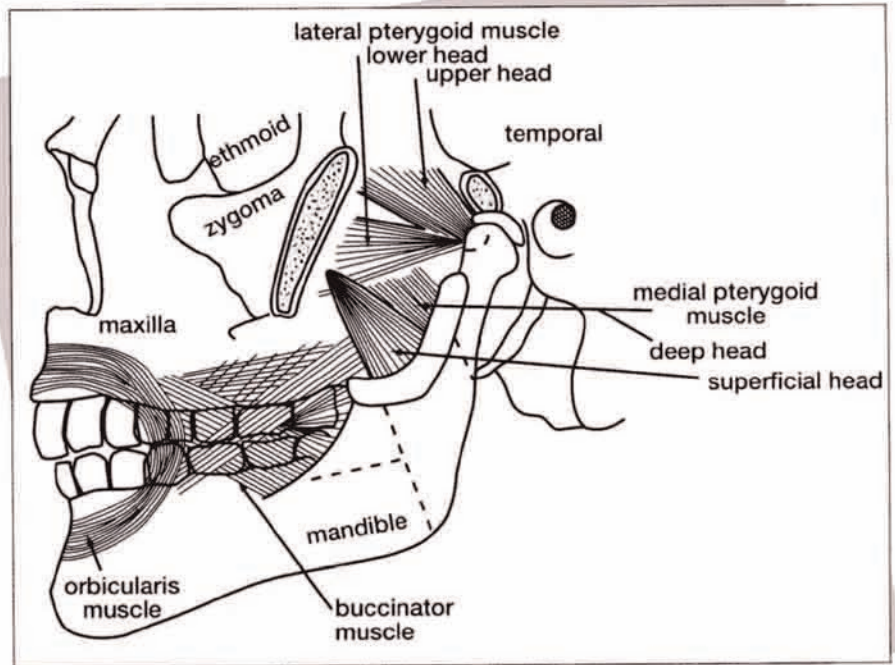


Figure 7

### The Lateral

### Pterygoid Muscle -

The lateral pterygoid muscles (one on each side of the head) pass between these two parts of the medial pterygoid muscles. They are almost anatomically horizontal, while the temporal, masseter and medial pterygoid muscles are more nearly anatomically vertical. The lateral pterygoid muscles arise from two heads anteriorly. One head is attached to the great wing of the sphenoid on its undersurface and from the infratemporal crest on that side of the head. The other head of the muscle arises from the lateral pterygoid plate. These muscles run posterior and somewhat laterally on both sides of the head to insert on the coronoid processes of the temporal bones. Thus, they act antagonistically to

the posterior temporalis muscle. The lateral pterygoid muscle acts to pull the coronoid process forward, thus assisting in mouth opening, whereas the posterior temporalis muscle pulls the coronoid process back and up, which assists in mouth closure.

"The lateral pterygoid muscle acts to pull the coronoid process forward, thus assisting in mouth opening, whereas the posterior temporalis muscle pulls the coronoid process back and up, which assists in mouth closure."

**The Buccinator Muscles -** The buccinator muscles form the side walls of the mouth and aid in containing and positioning food in the mouth as we chew and swallow. They also assist when we blow a trumpet or suck a lollipop. The buccinator muscle attaches to the alveolar ridges of the maxillae and mandible, and to the pterygomandibular raphe on both sides of the mouth. This raphe is a band of tough connective tissue extending from the hamulus of the medial pterygoid plate of the sphenoid to the back part of the outside surface of the mandible.

The innervation to the temporalis muscles, masseter muscles and both medial

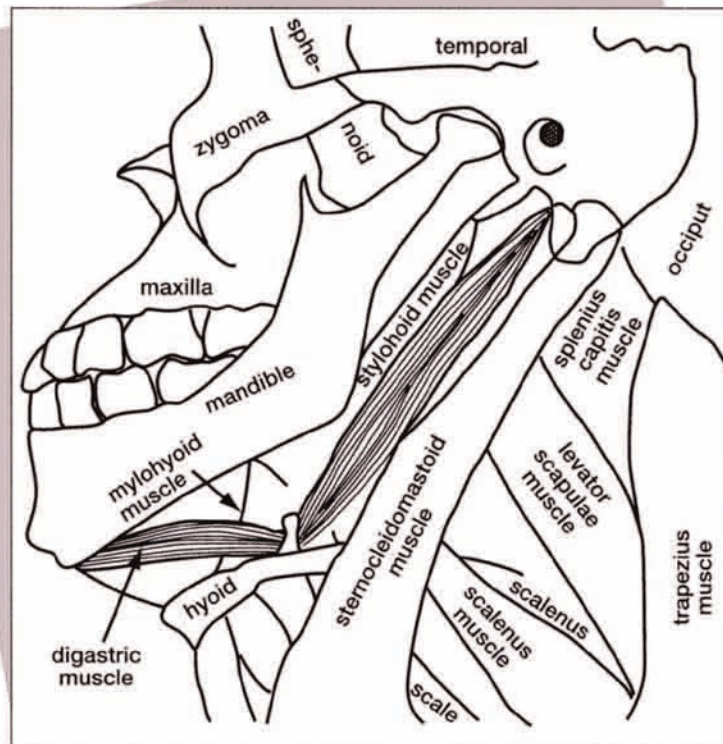
and lateral pterygoid muscles are from the trigeminal cranial nerve system. The innervation to the buccinator muscles is from the facial cranial nerve system.

There are many other muscles of facial expression that are innervated by the trigeminal and the facial cranial nerve systems. These muscles play lesser rolls in the masticatory system. They do such things as part your lips when you take a bite, and so on.

**The Suprahyoid Muscles** - The floor of the mouth is significant in the temporomandibular joint system in that it has the capability to powerfully draw the mandible backward, thus driving the mandibular condyle into the posterior part of the fossa of the temporal bone as it contributes to the joint. In so doing, these muscles of the floor of the mouth can cause injury to the joint surfaces and to the retrodiscal elastic tissue, which may become trapped between the temporal bone and the mandibular condyle.

The muscles in the floor of the mouth are anchored to the hyoid bone, which must be stabilized for posteriorly directed abnormal temporomandibular joint compression to occur. The muscles in the floor of the mouth, which can cause this retraction of the mandible, are counterbalanced or antagonized largely by the constrictor pharyngeus medius muscles that connect the hyoid bone with the back of the neck.

Therefore, when the retrohyoid muscles contract, they prevent the hyoid from moving forward when the muscles of the floor of the mouth (mylohyoideus, geniohyoideus and anterior digastricus) contract. When the hyoid is stabilized these latter muscles, when contracting, move the mandible posteriorly, and if the contraction is forceful enough they cause mandibular condyles to compress the temporomandibular joints. If the disc is trapped between the two bones (the temporal and the condyle) it can be damaged, as can the retrodiscal elastic tissue by constant or repeated compression.



**Figure 8**

This view from above is from beneath the chin.

**Figure 8: The Muscles of the Floor of the Mouth—Suprahyoid Muscles**



## Figure 9: The Muscles of the Floor of the Mouth—Suprahyoid Muscles

This view is from slightly above and inside the mouth.

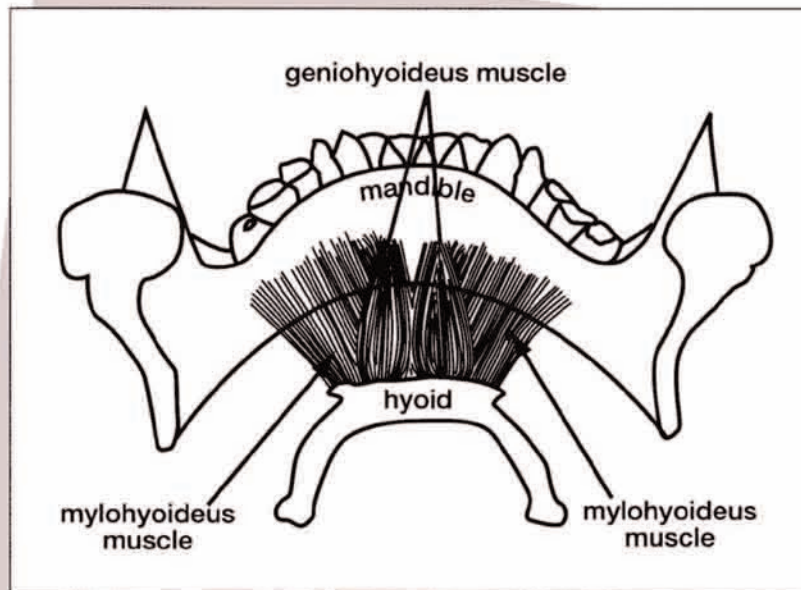


Figure 9

## The Ligaments

**T**he ligaments of the temporomandibular joint are: the temporomandibular joint capsule, temporomandibular ligament, sphenomandibular ligament and stylo-mandibular ligament.

**The Temporomandibular Joint Capsule** - The temporomandibular joint capsule is a rather tough, fibrous envelope that attaches above to the circumference of the joint surface of the temporal bone. Below, the capsule attaches all the way around the neck of the mandible just beneath the condyle. In between, it attaches to the circumference of the disc. This capsule is well supplied with blood vessels and nerves. The sensory receptors of the capsule refer in to the trigeminal nerve system. It is very pain-sensitive and is quite capable of keeping the trigeminal ganglion (which I think of as an auxiliary brain) on ready alert, hyperirritable and thus facilitated.

Above the disc the capsule is loose and

billowy. This allows a rather free gliding action for the disc on the temporal bone surface. Below the disc the capsule is much more taut since the disc moves very closely with the condyle of the mandible.

Synovial fluid is secreted within both intracapsular compartments. This fluid lubricates, supplies nutrition, carries away waste products, acts as a medium for leukocyte movement, and serves to inflate the joint capsule.

It has been previously mentioned that the retrodiscal elastic tissue connects the back part of the disc to the capsule and allows the disc to move forward in response to lateral pterygoid muscle contraction. When the muscle relaxes, the elastic quality of the retrodiscal tissue returns the disc to its posterior resting position. The retrodiscal tissue is in two layers. The upper layer is elastic and the lower layer, which attaches to the posterior condyle as well as the posterior part of the disc, prevents these structures from moving too far forward because it is not elastic.



### The Temporomandibular Ligament -

This ligament strengthens the anterolateral part of the capsule. It is actually a thickening of the capsule. It connects the zygomatic process of the temporal bone to the neck and condyle of the mandible. Part of the ligament diverges and attaches to the ramus of the mandible at its axis of rotation. This ligament helps to prevent posterior dislocation of the mandible.

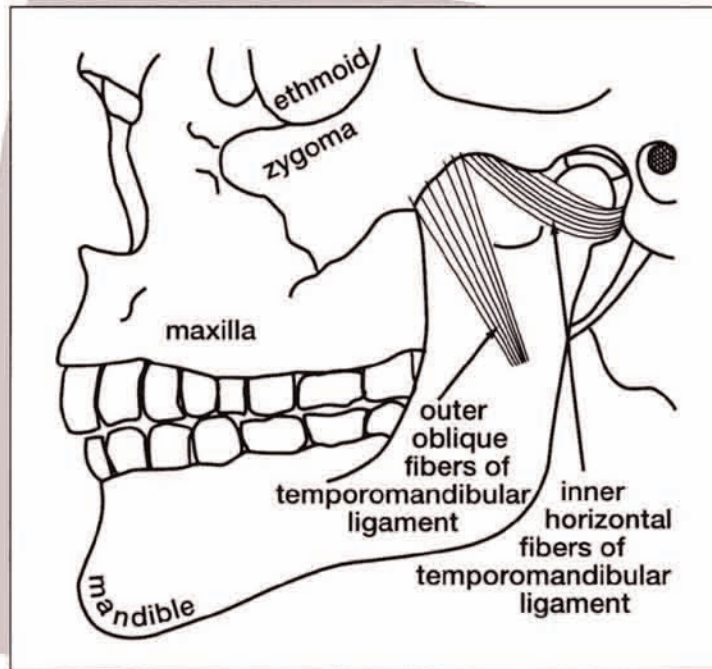
### The Sphenomandibular Ligament -

This is a thin, flat ligament oriented almost vertically. It connects the spine of the sphenoid bone to the inner surface of the ramus of the mandible near the mandibular axis of rotation. It helps to suspend the mandible from the base of the skull and prevents inferior dislocation of the condyles and the total mandible. This is the ligament that may have fibers that penetrate into the middle ear and attach to the malleus (one of the tiny bones in the middle ear). It may contribute to tinnitus when this occurs.

**The Stylomandibular Ligament -** This ligament connects the styloid process of the temporal bone to the posterior surface of the lower end of the ramus and the angle of the mandible. It also acts to suspend the mandible from the skull.

Clearly, problems with any of these ligaments can produce craniosacral system dysfunction due to these temporal and sphenoidal bone attachments.

I have taken the liberty of assigning the



**Figure 10**

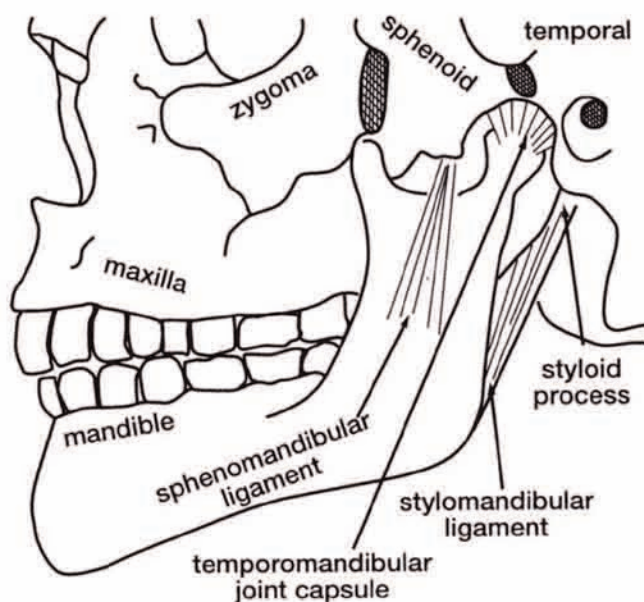
**Figure 10:  
Ligaments of the  
Temporomandibular  
Joint**

majority of causes of, and contributing factors to, temporomandibular joint dysfunction and the resulting syndrome into the following major categories:

- Craniosacral System Dysfunction
- Stress
- Neurogenic Problems/  
Dysfunctions
- Post-Traumatic Problems/Residuals
- Structural/Somatic Problems and  
Dysfunctions
- Degenerative Problems/Diseases
- Dental Problems

"The sensory receptors of the [TMJ] capsule refer in to the trigeminal nerve system. It is very pain-sensitive and is quite capable of keeping the trigeminal ganglion (which I think of as an auxiliary brain) on ready alert, hyperirritable and thus facilitated."

**Figure 11:**  
**Ligaments of the**  
**Temporomandibular**  
**Joint**



**Figure 11**

## TEMPOROMANDIBULAR JOINT SYNDROME: CAUSES AND CONTRIBUTING FACTORS

Now, I should like to present a brief discussion of each topic and include suggestions about the efficacious use of a variety of treatment modalities for each category.

### Craniosacral System Dysfunction -

The bones of the skull that are the most directly involved with the temporomandibular joints are, of course, the temporal bones and the mandible. The temporal bones are the most likely offenders in craniosacral system dysfunctions. The contributions of the bilaterally placed temporal bones to the temporomandibular joints are located forward about two to four centimeters from each temporal bone's axis of rotation. Therefore, since the joint surfaces of the temporal bones are located in eccentric positions, when the temporal bone or bones are restricted into asymmetrical positions in relationship to one other, they provide malaligned joint surfaces for

the temporomandibular joints on both sides. This malalignment results in mandibular imbalance and undue wear and stress upon the joints. Temporal bone dysfunction can result from almost any problem within the craniosacral system, be it osseous or membranous. Only a thorough evaluation of the whole system and the total body's contributions to craniosacral system dysfunction will yield the primary etiology of the problem. Remember, temporal bones can also be forced into abnormal positions when the muscles and ligaments that

attach to them (as have been reviewed in the previous section) present with abnormal strains and tensions. CranioSacral Therapy is aimed at temporal bone release so that normal function can be restored no matter what is found to be the primary cause.

The mandible, the other bone which contributes directly to the temporomandibular joints, is a single bone with one joint on each end. Therefore, you cannot distort one joint without causing a problem with the joint at the other end of the mandible. CranioSacral Therapy uses techniques to release and balance the joints at both ends of the mandible, as well as techniques that will release undue muscle and ligament tensions upon this lower jaw bone.

The hard palate is very much at the mercy of the sphenoid bone with which it articulates at both sides and (via the vomer) in the middle. Since the sphenoid is a major player in the craniosacral system, it is important to evaluate the total body's effect on that system as well as the total system, and its effect upon the function of



the hard palate. Distortions in sphenoid function or position often cause hard palate malalignment, which then results in malocclusion of the teeth and secondary temporomandibular joint problems.

Also within the domain of CranioSacral Therapy we have the balancing of all of the muscles of mastication so that bruxism, disc position and temporomandibular joint compression are effectively treated by CranioSacral Therapy.

**Stress** - Stress can be physiological as might be imposed by visceral problems such as gall stones, kidney dysfunction, arteriosclerotic heart disease and the like. Stress can be physical such as that which is induced by poor posture, perhaps secondary to a shortened leg, etc. Psychoemotional stress is yet another category of the problem, which is due to life frustrations, neuroses, harbored destructive emotions like chronic anger and so on. Stress can also be induced by the environmental conditions in which we live and work. Examples of this type of stress might be the continuous breathing of polluted air, working in a noisy environment and so on. We have lots of examples of externally imposed stresses to our physiology, which require adaptive energy in order to survive.

Stress, no matter what the cause or the type, exacts a toll from the body. Energy is required to cope. It is well known that chronic stress may cause heart disease, stomach ulcers, spastic bowel syndromes, adrenal insufficiency, etc. What has not been thoroughly considered is that stress can cause temporomandibular joint problems. It is really simple. Teeth or

jaw clenching is a natural response to increased stress. This response chronically compresses the temporomandibular joints, which in turn causes the joint surfaces, the discs and, especially, the retrodiscal elastic tissues to be placed in jeopardy.

When excess stress is a factor we must consider the use of stress management techniques. Among these modalities we find therapeutic massage for relaxation and release, CranioSacral Therapy to reduce sympathetic nerve tone, SomatoEmotional Release to alleviate traumatic tissue memories and psychoemotional problems, hypnotherapy and/or biofeedback to develop conscious control of muscular hypertonus, psychotherapy, and counseling. Any or all of these and similar techniques should be considered for use, depending upon the patient and the availability of therapeutic modalities.

---

*"CranioSacral Therapy is aimed at temporal bone release so that normal function can be restored no matter what is found to be the primary cause."*

---

### **Treatment Modalities Include:**

- CranioSacral Therapy
- SER® and Imagery & Dialogue
- Energy Cyst Release
- Myofascial Release
- Acupuncture
- Postural Integration Methods
- A Variety of Manipulative Therapies
- Release of all Facilitated Segments
- Psychotherapy/Hypnotherapy
- Biofeedback/Meditation
- Dental Work: Appliances, Surgery
- Nutritional Support



### Neurogenic Problems - The

trigeminal nervous system is very much in charge of the function of the masticatory system and, therefore, of the temporo-mandibular joints. This system has the most numerous connections with the reticular alarm system of any of the cranial nerve systems. Since our nervous systems are pretty much derived from the same foundations as all mammals, it is clear that humans retain some of the characteristic instincts that are common to most of the mammalian class of the animal kingdom. In terms of significance to the temporo-mandibular joints, this means that our reticular alarm systems, when activated, cause us to clench our teeth. This results in excessive compression at the temporo-mandibular joints and, eventually, a wearing down of the vertical stature of the teeth — which means, with loss of vertical stature, the normal closing of the mouth without excessive teeth clenching causes excessive joint compression.

Factors that feed into and activate the reticular alarm system are fear, anger, aggressiveness, facilitation of spinal cord segments due to visceral dysfunctions or musculoskeletal problems, ongoing pain, autonomic nerve dysfunction, and a touch of paranoia or excessive weariness.

Treatment modalities useful for these problems involve all of the musculo-skeletal treatment techniques, Myofascial Release techniques, therapeutic massage of any type, CranioSacral Therapy, SomatoEmotional Release, Energy Cyst Release, hypnotherapy, biofeedback, and a wide range of psychotherapeutic techniques.

### Post-Trauma Problems - Tissues

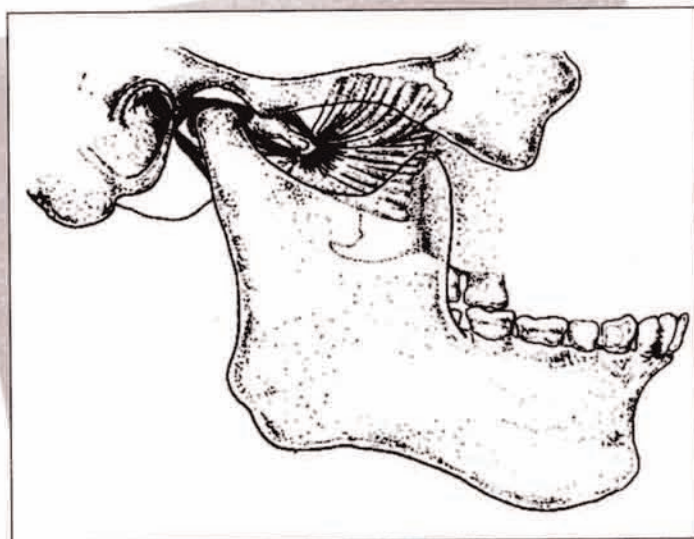
all over the body remember traumatic experiences on an energetic level, as well as on a more gross structural level. All aspects of previous trauma must be released and resolved. This means fear or anger, etc., that occur at the time of trauma, as well as the structural injury and its residua. In this arena, Somato-Emotional Release with therapeutic imagery and dialogue have, in my own experience, been most effective in ridding the patient of the residual effects of trauma.

Retained trauma often provides energy that overactivates the reticular alarm system and elevates body stress responses. Hence, it is very common that previous traumas that continue to affect the body and temporomandibular joints are often the foci of these effects. All of the aforementioned modalities may be useful here, as well as structural corrections of mouth injuries by dentists. Clearly, post-traumatic events cannot be completely separated from the other categories. The body is a unit and

### TMJ Dysfunction Syndrome includes:

- TMJ pain, noise, immobility
- Head, neck & referred pain
- Visual, auditory, equilibrium, attention and mental disturbances
- Personality and emotional disturbances

May be primary problem or may be secondary to a wide variety of problems, as indicated.





is integrated with mind and spirit. Therefore, we must consider the patient as a whole being.

**Structural/Somatic Problems and Dysfunctions** - Many of the problems within this category have been mentioned previously. Please forgive the redundancy, but I feel that a specific search for structural/somatic problems as causes for temporomandibular joint dysfunction is definitely in order. Certainly, all aspects of the temporomandibular joints, masticatory system, craniosacral system and the total musculoskeletal system must be evaluated as possible contributors to temporomandibular joint syndrome.

As these problems are uncovered, a wide variety of efficacious treatment methods can be applied. I have found osteopathic manipulation (probably because I was originally trained as an osteopath), chiropractic adjustment, Myofascial Release, Strain/ CounterStrain, Muscle Energy, therapeutic massage (of all types) and CranioSacral Therapy to be of primary importance. All other methods that work are most welcome.

**Degenerative Diseases** - In this category we include inflammatory and degenerative arthritic diseases. We must also consider that most, if not all, of the autoimmune diseases may affect the temporomandibular joints. In addition, we must consider contributions to temporomandibular joint dysfunction that result from allergies and toxic responses.

Any or all of these problems may affect the temporomandibular joints, either directly upon the involved bony joint surfaces, the intra-articular discs, or upon connective tissues that relate directly to the joints. In addition, we must also keep in mind the indirect routes via the cranio-

sacral system, nervous system, all kinds of stresses and their effects upon total body function, as well as structural/somatic problems, trauma and post-traumatic residua.

Any or all of these factors are very capable of contributing to dysfunction and degeneration of the temporomandibular joints. Holistic treatment for temporomandibular joint syndrome must therefore include all forms of bodywork, mind work, emotional work, spiritual work and the integration of all of these works in addition to allopathic and natural medicines, as well as dentistry and surgery. To focus on any one approach is to reduce the patient's chances for the best possible recovery.

**Dental Problems** - I am hesitant to discuss how dentists should treat temporomandibular joint syndrome. I only know that, when direct orthodontic, occlusal and/or surgical interventions are put into play before the craniosacral system is functioning at its optimal level and is symmetrically balanced as best it can be, the work of the dentist with appliances and/or surgical procedures must often be redone as the masticatory system and its involved structures change in response to the craniosacral work. The same is true of the vast array of bodywork as it is effectively applied to the patient, as well as body-mind integrative work, such as SomatoEmotional Release, Energy Cyst Release, release of tissue memory, biofeedback, hypnotherapy and all the rest.

This does not exclude the dentist from being a part of the treatment team; it only means that he/she should recognize that occlusions, temporomandibular joint vitality, bruxism, compressive forces related to the masticatory system and so

---

**"Holistic treatment for temporomandibular joint syndrome must therefore include all forms of bodywork, mind work, emotional work, spiritual work and the integration of all of these works in addition to allopathic and natural medicines, as well as dentistry and surgery."**


---

"The temporomandibular joint syndrome may be primary or it may be just the tip of the iceberg. The syndrome is a part of the whole person, and it is the whole person that must be evaluated and treated."

on will most likely be in a state of change as a result of the non-dental work. Therefore, the work that the dentists do should be temporary and complementary to the holistic approach, rather than exclude that approach.

In CranioSacral Therapy, we specifically mobilize teeth in their sockets and encourage these teeth to find their natural resting places in the mouth. This happens and it changes the occlusion toward that which nature intended. Permanent braces, use of overly restrictive splints, etc., inhibit the natural movement of mobilized teeth and therefore interfere with a more holistic process.

SomatoEmotional Release, Energy Cyst Release and the release of tissue memory involving distant body parts also cause teeth to move if they are free to do so. I had a very recent personal experience wherein my dentist allowed me to convince him to put in a removable partial plate that replaced two lower molars that had been removed some years ago. He had wanted to put in two non-removable bridges across these gaps in the chewing/grinding surfaces of my back teeth. That he didn't was lucky for me, because in the past few months I have been releasing the residua of an old fracture of my right, distal femur (from age 16) and its accompanying knee and hip injuries. Lo and behold, during the space of a month the molars behind the old extraction (at least 10 years old) moved forward more than a millimeter in my mandible. This astonished the dentist, and it looks like these molars will continue to move for a while. Had there been a permanent bridge rather than a partial plate, which I stopped wearing because it became uncomfortable, I'm sure these teeth would not have been allowed to move. I'm also sure this inhibition of a natural adaptational



**Dr. John E. Upledger**

process would have cost me somewhere in my body.

In any open-minded case, dentists are essential members of the holistic temporomandibular joint syndrome treatment team. The temporomandibular joint syndrome may be primary or it may be just the tip of the iceberg. The syndrome is a part of the whole person, and it is the whole person that must be evaluated and treated.

Thanks for listening,

John E. Upledger, D.O., O.M.M.



## JOHN E. UPLEDGER, D.O., O.M.M.

Dr. Upledger has been recognized as an innovator and leading proponent in the investigation of new therapies. His development of CranioSacral Therapy in particular has earned him an international reputation. Dr. Upledger is a Certified Specialist of Osteopathic Manipulative Medicine, an Academic Fellow of the British Society of Osteopathy, and a Doctor of Science. He has also served on the Alternative Medicine Program Advisory Council for the Office of Alternative Medicine at the National Institutes of Health.

Dr. Upledger specializes in numerous complementary therapies, including osteopathic manipulation, CranioSacral Therapy, SomatoEmotional Release®, acupuncture and preventive medicine.

Although much of his experience has been garnered through private clinical practice, Dr. Upledger served from 1975 to 1983 as a clinical researcher and Professor of Biomechanics at Michigan State University. During those years he supervised a team of anatomists, physiologists, biophysicists and bioengineers in experiments testing the existence and influence of the craniosacral system.

The results of those scientific studies explained the function of the craniosacral system and its use in evaluating and treating poorly understood malfunctions of the brain and spinal cord. Dr. Upledger went on to develop and refine CranioSacral Therapy and complementary modalities that The Upledger Institute now teaches worldwide to a diversified group of healthcare professionals.

His textbooks include: *CranioSacral Therapy*, *CranioSacral Therapy II: Beyond The Dura*, *SomatoEmotional Release and Beyond*, and *A Brain Is Born*. He has also written a book that explains CranioSacral Therapy to the general public: *Your Inner Physician and You*.

## THE UPLEDGER INSTITUTE, INC.

The Upledger Institute is a health resource center dedicated to the advancement of complementary techniques. It's recognized worldwide for its groundbreaking continuing-education programs, clinical research and therapeutic services.

The Institute was founded in 1985 by John E. Upledger, D.O., O.M.M. Today it conducts hundreds of workshops each year, educating healthcare practitioners of all disciplines. Alumni include osteopaths, medical doctors, doctors of chiropractic, doctors of Oriental medicine, psychiatrists, psychologists, dentists, physical therapists, occupational therapists, acupuncturists, massage therapists and other professional bodyworkers.

The Upledger Institute HealthPlex Clinical Services in Palm Beach Gardens, Fla., staffs physicians and therapists educated in a wide range of conventional and complementary methods. In addition to private sessions, the clinic offers a series of intensive-therapy programs, including those addressing brain and spinal cord dysfunction, learning disabilities, autism, therapist rejuvenation, post-traumatic stress disorder, cancer recovery and pain. UI HealthPlex also provides infancy-to-preschool evaluations, and helpful one-day ShareCare™ seminars designed for the general public.

The Upledger Foundation represents the non-profit research arm of the Institute. It's committed to the development of new therapies and community-outreach projects designed to enhance total health. The Upledger Foundation also assists with financial aid to qualified patients in need.



**Call today for  
product information,  
educational programs  
or therapeutic  
services.**

Seminar Registration  
and Product Orders  
1-800-233-5880, ext. 4545

Administration  
(561) 622-4334

Administration Fax  
(561) 622-4771

HealthPlex Clinical Services  
(561) 622-4706

**A special thanks to  
Alice Quaid, P.T., for  
the illustrations in  
Figures 1-11.**